



## Saudi Medical Journal of Students (SMJS)

Official Journal of Faculty of Medicine University of Tabuk

ISSN: 1658-8274 (Print version); 1658-8282 (Electronic version)

### EPONYMOUS SIGNS OF ACUTE CHOLECYSTITIS – A REVIEW

Sajad Ahmad Salati<sup>1</sup>, Khalid Alkhalifah<sup>2</sup>, Abdul Majeed Salem Almousa<sup>3</sup>

<sup>1</sup>Professor of Surgery, Unaizah College of Medicine and Medical Sciences, Qassim University, Saudi Arabia

<sup>2</sup>MD-3 Student, Unaizah College of Medicine and Medical Sciences, Qassim University, Saudi Arabia

<sup>3</sup>MD-2 Student, Unaizah College of Medicine and Medical Sciences, Qassim University, Saudi Arabia

\*Corresponding author: Khalid Alkhalifah, Email: Khalid.Alkhalifah45@gmail.com, Mobile: +966538199945, Postal Address: 2428, Al-Hazm Dist. Ar Rass, Al Qassim, 58882, Saudi Arabia

### ABSTRACT

Medical eponyms are honorific terms that usually refer to the physicians who have contributed significantly to the identification of a particular disease or management tool. With respect to acute cholecystitis, three eponymous signs are mentioned in the literature, namely Murphy's sign, Boas' sign, and Collin's sign. The article reviews the historical background, principles, techniques, clinical application, and pitfalls of each of these signs.

**Keywords:** Eponymous sign; Acute cholecystitis; Cholelithiasis; Murphy's sign; Boas' sign; Collin's sign.

To cite this article: Salati SA, Alkhalifah K, Almousa AS. Eponymous Signs Of Acute Cholecystitis – A Review. Saudi Med J Students. 2023;3(2):44-55

### INTRODUCTION

Clinical skills training is an important component of the medical curriculum. The skills need to be properly mastered, alongside clinical competencies and research activities, as they represent the ingenious method of disease detection, in spite of vast advances in imaging and laboratory tools.

In relation to these skills, physical signs associated with medical eponyms have a long-standing tradition and are commonly encountered in clinical practice. A medical eponym is an honorific term that usually refers to the physician who has contributed

significantly to the identification of the disease and under the right circumstances, a particular disease becomes well known through the name of that physician [1-2].

Eponymous signs elicited during the clinical examination tend to leave a mental imprint by adding a different dimension and represent a meaningful way to impart education to medical students while instilling a sense of excitement and life-long learning; the students see the examination as a potential method of diagnosis like other diagnostic tools and gadgets [3].

Cholelithiasis and its complications form an important spectrum of surgical disorders and there are three eponymous signs associated with them, namely Murphy's sign, Boas' sign, and Collin's sign. Murphy's sign and Boas' sign are well-established in clinical practice and Collin's sign is less known due to its recent introduction in literature. This article briefly reviews the technique, clinical application, and implications of these signs in current surgical practice brief and mentions some historical background information about the physician related to these signs.

## DATA SOURCES

PubMed, Medline, ResearchGate, online Internet word searches (Google), and bibliographies from bibliographies of the prominent textbooks of physical examination, surgery, and gastroenterology, were used to search for articles in English language using the Medical Subject Heading (MeSH) terms (Murphy's Sign, Boas' Sign, Collin's Sign, Acute cholecystitis, Medical Eponyms). No time limits were applied.

## 1. Murphy's Sign

### i. Historical Background Information

Prof. John Benjamin Murphy (1857–1916) was one of the famous and extraordinary surgeons from the USA who made significant contributions to surgical sciences, championed specialization, and emphasized the importance of technical excellence, thereby turning surgery into a performance art [4].

He has made valuable contributions in the fields of vascular, urologic, thoracic, neurologic, and orthopaedic surgery, and his

name is associated with multiple eponyms like Murphy's punch for kidney percussion, Murphy's syndrome, Murphy's sign test for metacarpals, and Murphy's sign for gall bladder. He also devised instruments that are named after him, like Murphy's buttons for intestinal anastomosis, Murphy-Lane bone skid, and Murphy drip. His writings and surgical operations were enormous in number and extent, publishing 760 original articles in journals of repute besides writing a textbook on surgery [4-7].

Murphy's sign for gallbladder was described in 1903 and had an important role in the evaluation of acute cholecystitis. A sign based on a similar concept was described thirteen years before Murphy by Prof Bernard Naunyn (1839–1925) and is termed Naunyn's Sign [9-10].

The high regard in which Prof Murphy was held by his counterparts is best communicated by the remark of William J. Mayo [11-13]:

*'In reviewing Dr. Murphy's manifold activities and attempting to determine the greatest of his many great qualities, I think we may place first his ability as a teacher of clinical surgery and sum up by saying that in this respect he was without a peer. In his talented and discriminating writing we find evidence of his teaching on every hand. Dr. Murphy was the surgical genius of our generation.'*

After the death of Prof. Murphy, rich tributes were paid by Lord Berkley Moynihan [14] in a memorial oration before the American College of Surgeons in 1920, as follows:

*"Among those who knew him well, he was deeply respected and admired, rather than loved... Murphy was beyond question the greatest clinical teacher of his day."*

## ii. Principle of Murphy's sign:

The diaphragm forces the liver down and in acute cholecystitis, as the sensitive gallbladder reaches the palpating fingers, the patient will experience pain and catch the breath suddenly as though respiration had been shut off.

## iii. Techniques of eliciting Murphy's sign

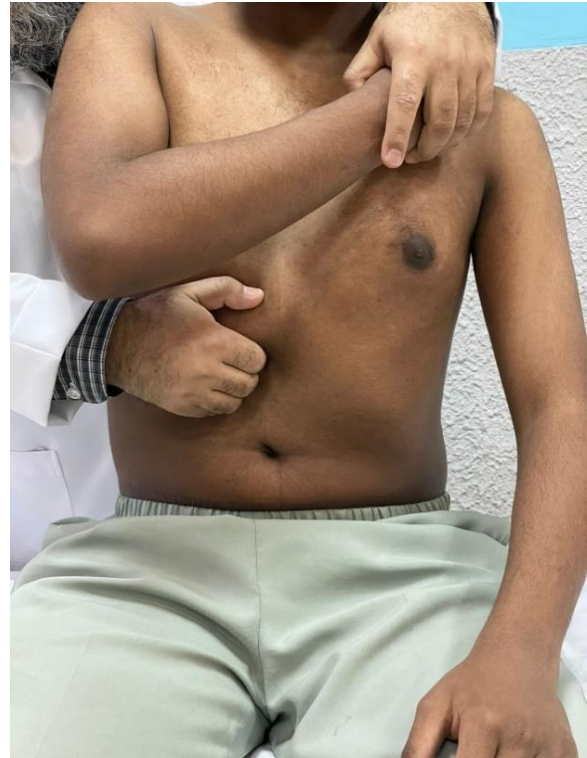### Deep grip palpation

In a patient, who is stable enough to assume an upright posture, the clinician stands behind the patient as shown in Figure 1. He then hooks up the fingers of his right hand under the costal margin at the tip of the ninth rib of the patient and requests him to take a deep breath [15-16]. Catch in the breath due to pain in acute cholecystitis would make the sign positive.

### Naunyn's modification of eliciting Murphy's sign

Naunyn's method of palpation bears the closest resemblance to the currently applied clinical examination skill (Figure 2).

The examination is conducted from the front in the patient in an upright or supine posture. The extended fingers of the clinician apply moderate pressure and palpate deeply (Figure 2) while the patient is requested to take a deep breath [17-18]. In acute cholecystitis, there would be a catch in the breath as is the deep grip palpation technique.

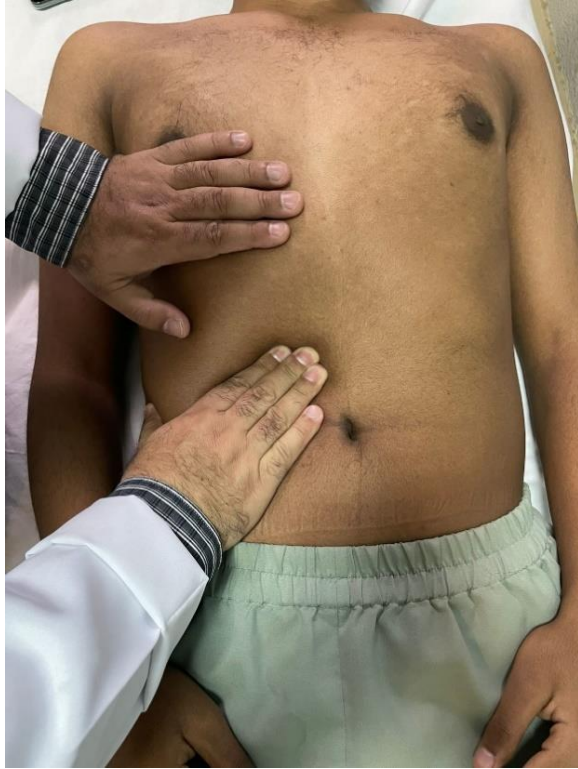

**Figure 1:** Murphy's Sign elicited by deep grip palpation technique

### Moynihan's modification of eliciting Murphy's sign

Acknowledging the techniques of right upper quadrant abdominal examination as described by Murphy (deep grip technique) as well as Naunyn, Lord Berkeley Moynihan (1865 – 1936) proposed his version (Figure 3) as follows:

The physician sits on the edge of the examination couch, to the right of the patient, and places his left hand over the patient's lowermost right anterior rib cage, so that the index finger is resting on the most inferior rib. The extended thumb lying along the rib margin is abducted and rotated in opposition

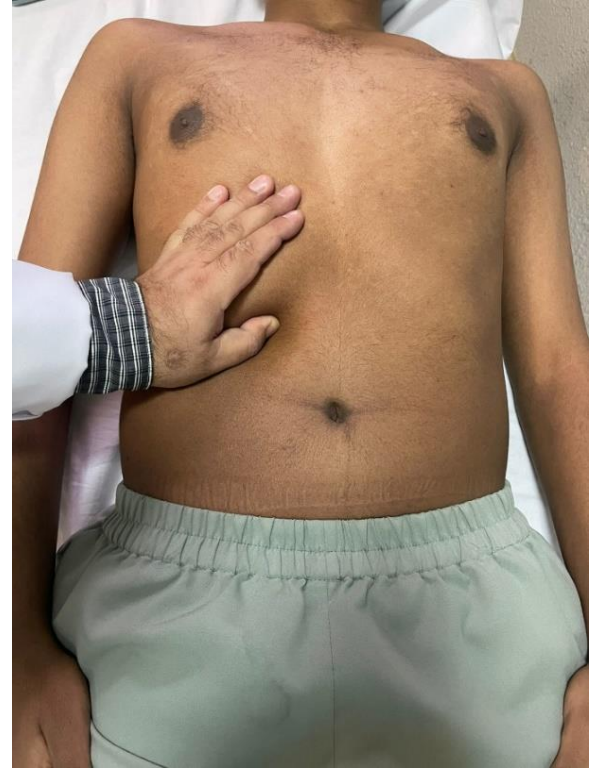

**Figure 2:** Murphy's Sign elicited by Naunyn's modified technique

down and into the patient's belly while the patient is requested to take a deep breath [17]. As the inflamed gallbladder presses against the thumb, the patient experiences pain enough to halt inspiration (usually at the end of inspiration). On repeating the maneuver but without pressing in with the thumb, if the patient can complete a full inspiration without any halt, then Murphy's sign is deemed as positive for acute cholecystitis.

#### **Murphy's Hammer Stroke Percussion Test**

This maneuver is based upon perpendicular percussion (Figure 4) and was described by Murphy himself [15,17].



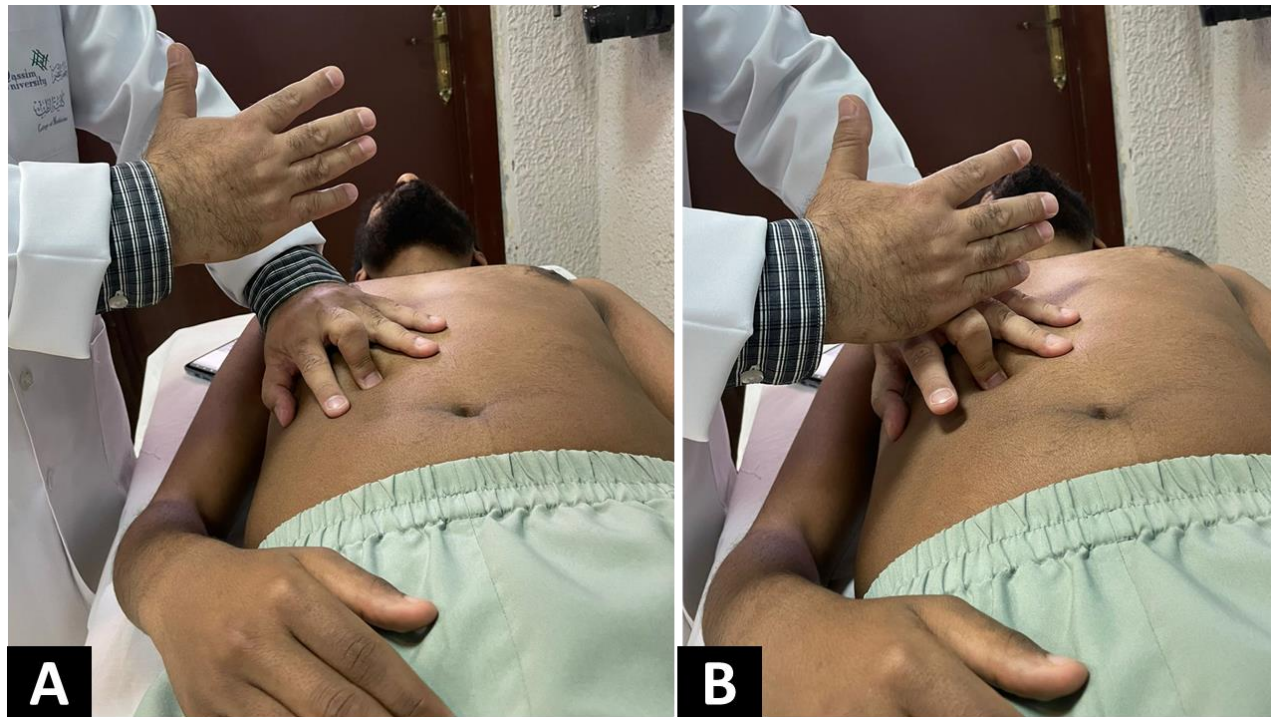
**Figure 3:** Murphy's Sign elicited by Moynihan's modified technique

The patient lies supine while the physician stands by the right side. The left hand is placed over the right midsubcostal region of the patient, with the middle finger, flexed (bent) perpendicularly at the tip of the ninth costal cartilage.

With the right hand, the dorsum of this bent finger (used as an anvil) is delivered hammer-like blows (percussed), when the patient is in deep inspiration. This causes great pain if the gallbladder is inflamed [9,17]. This method is uncommonly practiced in the current era but can be of high value in obese patients.

#### **iv. Efficacy of Murphy's sign**





**Figure 4 (A, B):** Murphy's Sign elicited by hammer stroke percussion technique

Many studies have assessed the efficacy of Murphy's sign. Singer et al. in 1996 conducted a retrospective analysis of 100 patients with suspected acute cholecystitis to assess the ability of various clinical and laboratory parameters to predict the results of hepatobiliary scintigraphy (HBS). 53 patients had a positive HBS, and 47 had a negative HBS. The presence of Murphy's sign was both sensitive (97.2%) and highly predictive (93.3%) of a positive HBS but was not documented in 35 cases. No other variable was found to be helpful in predicting the results of HBS [19].

A study by Adedeji and McAdam showed that Murphy's sign may be less sensitive in elderly people. It was a retrospective assessment of how the presence or absence of Murphy's sign affected the initial diagnosis of

acute cholecystitis in elderly patients. Diagnostic accuracy for acute cholecystitis was 80% but dropped to only 34% when the sign was negative. The positive predictive value of the test in elderly people was 0.58, with a sensitivity of 0.48 and a specificity of 0.79. Hence it was concluded that a positive Murphy's sign is useful in older people, but a negative sign requires to be taken with caution and further diagnostic tests need be performed promptly [20].

#### **v. Pitfalls while eliciting a Murphy's sign**

The physician trying to elicit Murphy's sign must be well versed with the proper technique. Improper techniques may lead to false-positive and else false-negative results. It may give false positives when the patient

actually has pain on inspiration on both the costal margins and the physician only examines the right side. To avoid this pitfall, the physician must examine both sides. False-negative results might be caused by the physician's fingers being placed at an incorrect location, thereby missing the contact with the gallbladder to avoid this pitfall the physician knows the correct hand placement [17]. Similarly, as mentioned in the above section, a false negative is common in the elderly and hence negative signs should not be relied upon definitely in that age group [20]

### **Sonographic Murphy's sign**

The sonographic Murphy's sign is identical to the clinical version of Murphy's sign, except that an ultrasonic transducer replaces the examiner's hand in this procedure. The sign is elicited by utilizing an ultrasonic transducer to palpate the right subcostal area while the patient is asked to inhale deeply. The ultrasound localizes the gallbladder and confirms it to be the origin of arrest in inspiration and the maximal tenderness objectively [17].

### **Efficacy and limitations of sonographic Murphy's sign**

The efficiency of sonographic Murphy's sign has been proved in numerous studies. In a study involving 497 patients with suspected acute cholecystitis, Ralls et al. [21] discovered that 98.8% of the patients exhibited a positive ultrasonographic Murphy's sign, making it a viable diagnostic test. They also found that the presence of gallstones and a positive Murphy's sign had a

92.2 % positive predictive value for acute cholecystitis, while the lack of gallstones and a negative Murphy's sign had a 95 % negative predictive value.

Bree [22] studied 200 patients with suspected acute cholecystitis and discovered that the sonographic Murphy sign has an 86 % sensitivity, a 35 % specificity, a 43 % positive predictive value, and an 82 % negative predictive value in acute cholecystitis. A specificity of 77 % was obtained when the Murphy sign was combined with gallstones. However, due to a large number of false positives and only a slight increase in specificity when accompanied by gallstones, Bree concluded that this tool is unreliable in distinguishing acute from chronic cholecystitis. Simeone et al. [23] found that in patients with abdominal pain and sonographic findings of cholecystitis, the absence of the Murphy sign increases the possibility of gangrenous cholecystitis.

Kendall and Shimp [24] conducted a study to determine the accuracy of Emergency Physicians (EP) performing focused right upper quadrant (RUQ) ultrasound in comparison to formal RUQ ultrasound performed by trained radiologists. They found that the sonographic Murphy sign elicited by the EPs had a sensitivity of 75% compared to the formal ultrasound sensitivity of 45% for acute cholecystitis. EPs were however less accurate in the detection of other sonographic findings (like gallstones, and gallbladder wall thickness), and the level of experience had little effect on sensitivity or specificity for detecting gallstones.

Noble et al. [25] also showed that EP-performed ultrasound may be more accurate in the assessment of sonographic Murphy's

sign, implying that EPs using bedside ultrasonography to diagnose acute cholecystitis can potentially save time, aid decision-making, and result in wise utilization of hospital resources.

Nelson et al. [26] investigated whether opioid analgesia affects the sonographic Murphy sign (SM) assessment and found no significant differences. Noble et al. [25] also arrived at an identical conclusion.

## 2. Boas' sign

### i. Historical Background Information

Ismar Isidor Boas (1858-1938) is revered as the founder of the medical specialization of gastroenterology. In 1886, he established the first specialized clinic for the study of digestive problems in Berlin. In 1895 he launched the medical journal *Archiv für Verdauungs-Krankheiten*, the first journal dedicated to the subject of gastroenterology, and in 1920 founded the German gastroenterological society.

He contributed significantly to the field of gastroenterology, including the description of *Lactobacillus acidophilus*, popularly known as the "Boas-Oppler bacillus." He developed the test meal for measuring gastric secretion, along with Carl Anton Ewald. His work on occult bleeding, which was the first to highlight the clinical value of this aberrant finding for the early identification of stomach cancer, is his most lasting scientific achievement. He gave the idea of the clinical sign in acute cholecystitis that is termed after his name as Boas' sign.

. He left Berlin for Vienna in 1936 with the rise of the Nazis and committed suicide there

in 1938 as Austria too succumbed to Nazi forces [27].

### ii. Principle of Boas' sign

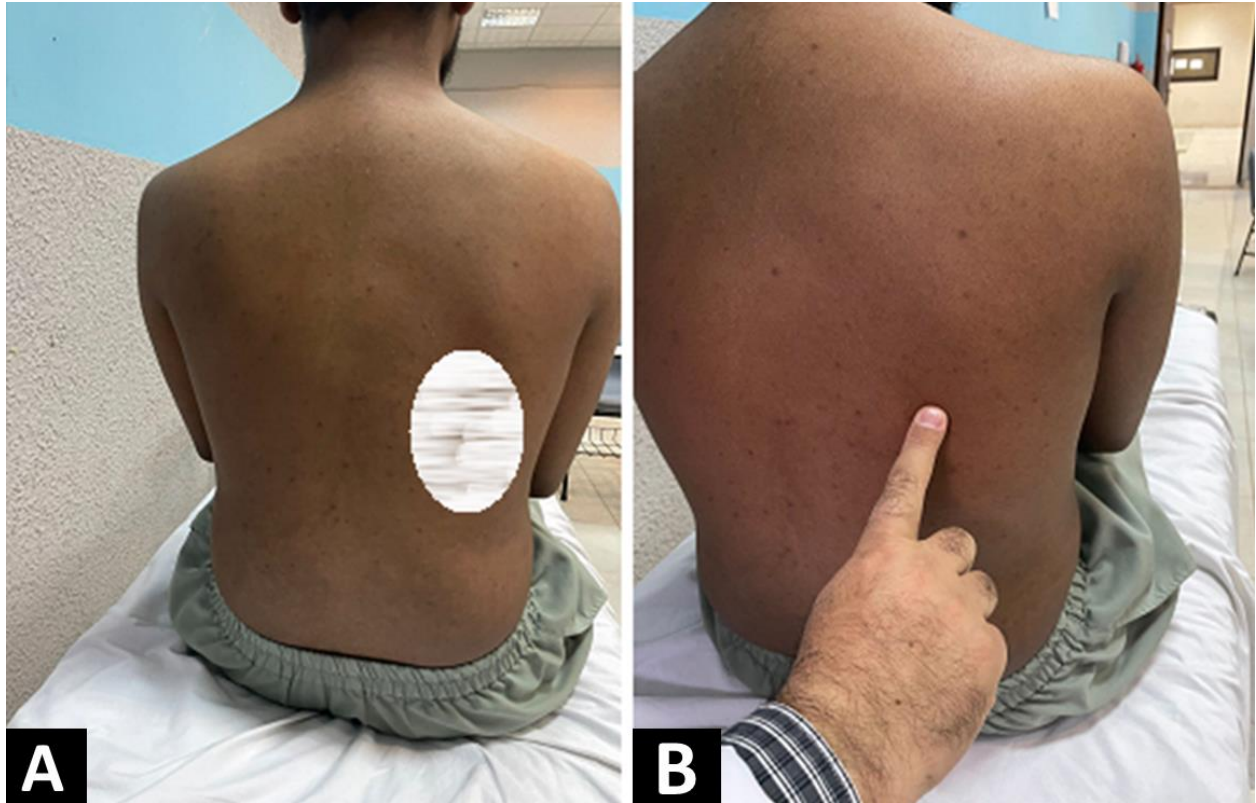
Boas' sign is based on the underlying principle that upper abdominal pain in symptomatic cholelithiasis may be referred to as the lower pole of the scapula or the right lower ribs (T7-T12) posteriorly [28-29].

### iii. Techniques of eliciting Boas' sign

- a) Original version: In its original explanation by Boas, the sign referred to the presence of pressure point tenderness located at the 12th thoracic vertebra extending to a region 2 or 3 finger-breadths distant from the vertebral bodies; spreading from this point to the right, and in some cases to the posterior axillary line [1].
- b) Contemporary version: More recently, Boas' sign is being described as hyperaesthesia to light touch in the right infrascapular area or even in the right upper quadrant, compared with that of the left, in acute cholecystitis [28, 30]. Technically, the sign is elicited by gently stroking the skin with the finger, when the patient complains of exquisite tenderness (Figure 5).

### iv. Efficacy of Boas' sign

Not many studies have been conducted that would have statistically validated the clinical efficacy of Boas' sign. One study reported that 7% of patients undergoing



**Figure 5:** Boas' sign - A: Infrascapular hyperesthesia is depicted schematically with shade, B: Hyperesthesia elicited by lightly stroking the infrascapular skin.

cholecystectomy exhibited a contemporary version (hyperesthesia) but no patient exhibited the original version (point tenderness) of Boas' sign [31].

#### **v. Pitfalls while eliciting a Boas's sign**

Herpes zoster typically presents with a prodrome (preherpetic neuralgia) consisting of hyperesthesia, paresthesias, burning dysesthesias, or pruritus along the affected dermatome(s). The prodrome generally lasts one to two days but may precede the appearance of skin lesions by up to three weeks and may lead to false-positive Boas' sign.

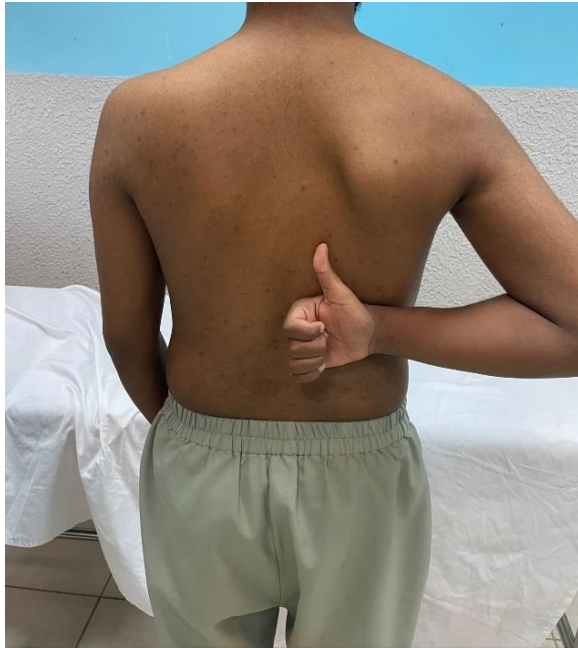Similarly, the gastric ulcer may give a false-positive result for the original version of Boas' sign. In fact, a tender to the area left of the 12th thoracic vertebra in patients with a gastric ulcer is termed Boas' point.

### **3. Collin's sign**

#### **i. Historical Background Information**

Patrick ('Paddy') Gerard Collins (1923 – 1999) was an Irish general surgeon and a Professor of Surgery at the Royal College of Surgeons in Ireland. He was interested in surgery of the biliary system, liver, and pancreas, and he contributed significantly to





**Figure 6:** Collin's sign (elicited when the patient directs his thumb towards a painful infrascapular area)

the surgical literature in the field of biliary surgery, particularly biliary reconstruction. His findings on the physiological implications of external bile loss and primary closure of the common bile duct will be remembered for a long time [32].

Prof Collin's dedication to these patients, with their complex and often life-long difficulties, cemented his reputation as a caring surgeon and a "professor of difficult surgery"[35]. Paddy worked with three legendary masters during the defining years of his early career (1955–59): Norman Cecil Tanner, the great gastric surgeon, and Richard Barley Channing Cattell of the Lahey Clinic in Boston, who exposed him to what would become a life-long interest - the

biliary duct reconstructive surgery, and William James Lytle, the hernia specialist. These legends were meant to remain his friends and role models for the rest of his life.

He made a substantial contribution to surgical education at both the undergraduate and postgraduate levels, and numerous foreign organizations and colleges recognized his abilities by inviting him to serve on their ruling councils or as an external examiner. He served as president of the Royal Academy of Medicine in Ireland and the Pancreatic Society of Great Britain and Ireland, as well as being a founding member and governor of the Irish chapter of the American College of Surgeons, a member of the Warner Cole Surgical Society in Chicago, and a member of the Royal College of Surgeons in Ireland's council. Prof Collin was described in an obituary published in the Irish Journal of Medical Science by Bonchier-Hayes D as the most charismatic of men, with charm, wit, intelligence, and a passionate commitment to surgery [33].

## ii. Principle of Collin's sign

Like Boas' sign, this sign is also based upon the principle that the upper abdominal pain in symptomatic cholelithiasis may be referred to as the lower pole of the scapula or the right lower ribs posteriorly [31].

## iii. Techniques of eliciting Collin's sign

Collin's sign is very easy to elicit and requires no special clinical skills. The patient is requested by the physician to point towards the area where the pain is felt and, if the

unprompted patient demonstrates the site by putting his hand behind the back with the thumb pointing upwards to the infrascapular area, the sign is considered positive (Figure6).

#### iv. Efficacy of Collin's sign

There aren't many studies on the clinical efficacy of Collin's sign, but there is a case-control prospective study performed by Gilani et al. [34] on 202 patients with symptomatic cholelithiasis and 200 control patients (with oesophagitis, gastritis, or duodenal ulcer) to assess the pain pattern with the help of a questionnaire. Collin's sign was found to be positive in 51.5 % of cholelithiasis patients. Only 7.5 % of those who did not have a gallstone had a positive Collin's sign ( $P < 0.001$ ). The odds ratio was 12.13 (a relative risk increase of 696%). That study concluded that Collins' sign is a useful discriminator in the diagnosis of gallstones.

#### v. Pitfalls while eliciting a Collin's sign

Shoulder pain/frozen shoulder is a common musculoskeletal condition that makes it difficult for the patient to place their hand behind their back, resulting in a false negative Collin's sign. Hepatic lesions such as cysts, on the other hand, may elicit referred shoulder discomfort due to a similarity in innervation to the gallbladder, resulting in a false positive indication [35].

#### CONCLUSION

Murphy's sign, Boas' sign, and Collin's sign are the three eponymous signs that can be elicited during the clinical examination to

diagnose acute cholecystitis. These signs constitute a meaningful means to teach clinical skills to medical students. However, for diagnosis, clinicians cannot depend exclusively on these signs, but must also consider laboratory and imaging studies.

#### ACKNOWLEDGMENTS

The authors express their gratitude to the simulated patients who allowed the use of images for academic purposes.

#### CONFLICT OF INTEREST

None

#### REFERENCES

1. Rastogi V, Singh D, Tekiner H, Ye F, Mazza JJ, Yale SH. Abdominal Physical Signs of Inspection and Medical Eponyms. *Clin Med Res*. 2019; 17(3-4):115-26. doi:10.3121/cmr.2019.1420
2. Ferguson RP, Thomas D. Medical eponyms. *J Community Hosp Intern Med Perspect*. 2014; 4(3):10.3402/jchimp.v4.25046. doi:10.3402/jchimp.v4.25046
3. Yale SH, Tekiner H, Yale E, Mazza J. Teaching physical examination signs as a novel applied diagnostic skill in medical education. *North Clin Istanbul* 2021; 8(1):111-12. doi: 10.14744/nci.2020.53325
4. Wulsin JH. The Remarkable Surgical Practice of John Benjamin Murphy. *JAMA*. 1993; 270(22):2741. doi:10.1001/jama.1993.03510220097049
5. Bhattacharya K, Bhattacharya N. John Benjamin Murphy - Pioneer of gastrointestinal anastomosis. *Indian J Surg*. 2008; 70(6):330-33. doi:10.1007/s12262-008-0094-9
6. Gordon RC. John B. Murphy: unique among American surgeons. *J Invest Surg*. 2006; 19(5):279-81. doi: 10.1080/08941930600889367. PMID: 16966205.

7. Siegel IM. John B. Murphy - early American orthopaedic surgeon. *Int Surg.* 1979; 64(1):83-85. PMID: 395125.
8. Musana K, Yale SH. John Benjamin Murphy (1857 - 1916). *Clin Med Res.* 2005;3(2):110-12. doi:10.3121/cmr.3.2.110
9. Morgenstern L. J. B. Murphy, M.D. Of buttons and blows. *Surg Endosc.* 1998 ;12(4):359-60. doi: 10.1007/s004649900672. PMID: 9543531.
10. Devlin HB. The Remarkable Surgical Practice of John Benjamin Murphy. *Ann R Coll Surg Engl.* 1994; 76(5):357.
11. George I, Hardy MA, Widmann WD. John Benjamin Murphy. *Curr Surg.* 2004 Sep-Oct;61(5):439-41. doi: 10.1016/j.cursur.2003.12.009. PMID: 15475090.
12. Rastogi V, Singh D, Tekiner H, Ye F, Kirchenko N, Mazza JJ, Yale SH. Abdominal Physical Signs and Medical Eponyms: Physical Examination of Palpation Part 1, 1876-1907. *Clin Med Res.* 2018;16(3-4):83-91. doi: 10.3121/cmr.2018.1423. PMID: 30166497; PMCID: PMC6306141.
13. Milloy F. The contributions of John B. Murphy to thoracic surgery. *Surg Gynecol Obstet.* 1990; 171(5):421-32. PMID: 2237729.
14. Moynihan B, John B. Murphy, Surgeon. *Surg Gynecol Obstet* 1920; 31:549-73.
15. Aldea PA, Meehan JP, Sternbach G. The acute abdomen and Murphy's signs. *J Emerg Med.* 1986;4(1):57-63. doi: 10.1016/0736-4679(86)90113-7. PMID: 3525662.
16. Jeans PL. Murphy's sign. *Med J Aust.* 2017; 206(3):115-16. doi: 10.5694/mja16.00768. PMID: 28208037.
17. Salati S, Kadi A. Murphy's sign of cholecystitis— a brief revisit. *Journal of Symptoms and Signs.* 2012; 1 (2): 53-56.
18. Bhattacharya K, Bhattacharya N. John Benjamin Murphy - Pioneer of gastrointestinal anastomosis. *Indian J Surg.* 2008; 70(6):330-33. doi: 10.1007/s12262-008-0094-9. PMID: 23133095; PMCID: PMC3452360.
19. Singer AJ, McCracken G, Henry MC, Thode HC Jr, Cabahug CJ. Correlation among clinical, laboratory, and hepatobiliary scanning findings in patients with suspected acute cholecystitis. *Ann Emerg Med.* 1996; 28(3):267-72. doi: 10.1016/s0196-0644(96)70024-0. PMID: 8780468.
20. Adedjei OA, McAdam WA. Murphy's sign, acute cholecystitis and elderly people. *J R Coll Surg Edinb.* 1996; 41(2):88-89. PMID: 8632396.
21. Ralls PW, Colletti PM, Lapin SA, Chandrasoma P, Boswell WD Jr, Ngo C, Radin DR, Halls JM. Real-time sonography in suspected acute cholecystitis. Prospective evaluation of primary and secondary signs. *Radiology.* 1985; 155(3):767-71. doi: 10.1148/radiology.155.3.3890007. PMID: 3890007.
22. Bree RL. Further observations on the usefulness of the sonographic Murphy sign in the evaluation of suspected acute cholecystitis. *J Clin Ultrasound.* 1995; 23(3):169-72. doi: 10.1002/jcu.1870230304. PMID: 7730462.
23. Simeone JF, Brink JA, Mueller PR, Compton C, Hahn PF, Saini S, Silverman SG, Tung G, Ferrucci JT. The sonographic diagnosis of acute gangrenous cholecystitis: importance of the Murphy sign. *AJR Am J Roentgenol.* 1989 ;152(2):289-90. doi: 10.2214/ajr.152.2.289. PMID: 2643262.
24. Kendall JL, Shimp RJ. Performance and interpretation of focused right upper quadrant ultrasound by emergency physicians. *J Emerg*

- Med. 2001; 21(1):7-13. doi: 10.1016/s0736-4679(01)00329-8. PMID: 11399381.
25. Noble VE, Liteplo AS, Nelson BP, Thomas SH. The impact of analgesia on the diagnostic accuracy of the sonographic Murphy's sign. *Eur J Emerg Med.* 2010; 17(2):80-3. doi: 10.1097/MEJ.0b013e32832e9627. PMID: 19584736.
  26. Nelson BP, Senecal EL, Hong C, Ptak T, Thomas SH. Opioid analgesia and assessment of the sonographic Murphy sign. *J Emerg Med.* 2005; 28(4):409-13. doi: 10.1016/j.jemermed.2004.12.009. PMID: 15837021.
  27. Hoenig LJ, Boyle JD. The life and death of Ismar Boas. *J Clin Gastroenterol.* 1988; 10(1):16-24. doi: 10.1097/00004836-198802000-00006. PMID: 3282002.
  28. Iyer H V. Boas' sign revisited. *Ir J Med Sci.* 2011; 180:301. <https://doi.org/10.1007/s11845-010-0640-x>
  29. Johnson CD. ABC of the upper gastrointestinal tract. Upper abdominal pain: Gall bladder. *BMJ.* 2001;323(7322):1170-1173. doi:10.1136/bmj.323.7322.1170
  30. Trowbridge RL, Rutkowski NK, Shojania KG. Does this patient have acute cholecystitis? *JAMA.* 2003 Jan 1;289(1):80-6. doi: 10.1001/jama.289.1.80.
  31. Gunn A, Keddie N. Some clinical observations on patients with gallstones. *Lancet.* 1972; 2(7771):239-41. doi: 10.1016/s0140-6736(72)91683-2. PMID: 4114503.
  32. O'Donnell B. *Irish Surgeons and Surgery in the Twentieth Century.* Gill & Macmillan; 2008 p 269-74.
  33. Bonchier-Hayes, D. Patrick G Collins (1923–99). *Ir J Med Sci* 2000; 169 :84. [doi: 10.1007/BF03170497](https://doi.org/10.1007/BF03170497)
  34. Gilani SN, Bass G, Leader F, Walsh TN. Collins' sign: validation of a clinical sign in cholelithiasis. *Ir J Med Sci.* 2009 Dec;178(4):397-400. doi: 10.1007/s11845-009-0404-7. PMID: 19685000.
  35. Gerwin RD. Myofascial and visceral pain syndromes: Visceral-somatic pain representations. *Journal of Musculoskeletal Pain.* 2002; 10(1-2):165-75, doi: 10.1300/J094v10n01\_13

